

# The Outcome and Complications of the Locked Plating Management for the Periprosthetic Distal Femur Fractures after a Total Knee Arthroplasty

Ashok S Gavaskar, MS Ortho, Naveen Chowdary Tummala, MS Ortho\*,  
Muthukumar Subramanian, Dip. Ortho

*Department of the Adult Joint Reconstructive Surgery, Parvathy Hospital, Chennai,*

*\*Dhruv Clinics, Chennai, India*

**Background:** The osteosynthesis of the periprosthetic fractures following a total knee arthroplasty can be technically difficult with the relatively small satisfactory outcomes and the high complication rates. The purpose of the study is to analyse the mid-term radiological and functional outcomes following the locked plating of the distal femur periprosthetic fractures after a total knee arthroplasty.

**Methods:** Records of 20 patients with a periprosthetic distal femur fracture following total knee arthroplasty (TKA) treated by the locked plate osteosynthesis were retrospectively evaluated. The union rate, complications and functional outcome measures were analysed.

**Results:** Successful union was achieved in 18 of the 19 patients available for the follow-up. The mean follow-up was  $39 \pm 10$  months. Significant reductions ( $p < 0.05$ ) in the range of motion and Western Ontario and McMaster Universities Western Ontario and McMaster Universities Arthritis Index (WOMAC) scores were evident in the follow-up. Secondary procedures were required in 5 patients to address the delay in union and the reduced knee range of motion. The osteosynthesis failed in 1 patient who underwent a revision TKA.

**Conclusions:** The satisfactory union rates can be achieved with the locked plate osteosynthesis in the periprosthetic distal femur fractures after TKA. Prolonged rehabilitation coupled with the un-modifiable risk factors can decrease the activity and satisfaction levels, which can significantly alter the functional outcome.

**Keywords:** *Total knee arthroplasty, Periprosthetic fractures, Locked plating, Distal femur fractures, Osteosynthesis*

The periprosthetic fractures around the knee are becoming more common with the ever-increasing incidence of the total knee replacements.<sup>1)</sup> Most of the fractures are the low-velocity fractures, which occur as a result of a combination of the torsional and axial loads.<sup>2)</sup> Osteoporosis, local osteolysis, inflammatory arthritis and the revision knee ar-

throplasty may serve as the additional risk factors.<sup>3,4)</sup> Distal femur fractures are the most common compared to the fractures of the proximal tibia and patella.<sup>5,6)</sup> The surgical management of these fractures can be broadly classified into the attempts at osteosynthesis and the revision arthroplasty with or without a use of the allografts. Nonoperative treatment is indicated only in the undisplaced fractures in the low-demand individuals and the patients who are unfit for surgery.<sup>7)</sup> Osteosynthesis of the periprosthetic distal femur fractures pose several challenges because of the compromised bone quality and the non-feasibility of using the standard methods of fracture stabilization. Surgical management of these fractures can be associated with the

Received January 25, 2012; Accepted September 24, 2012

Correspondence to: Ashok S Gavaskar, MS Ortho

Department of the Adult Joint Reconstructive Surgery, Parvathy Hospital,  
241 GST road Chrompet, Chennai, India

Tel: +91-9841552000, Fax: +91-044-23610360

E-mail: gavaskar.ortho@gmail.com

Copyright © 2013 by The Korean Orthopaedic Association

This is an Open Access article distributed under the terms of the Creative Commons Attribution Non-Commercial License (<http://creativecommons.org/licenses/by-nc/3.0>) which permits unrestricted non-commercial use, distribution, and reproduction in any medium, provided the original work is properly cited.

Clinics in Orthopedic Surgery • pISSN 2005-291X eISSN 2005-4408

high nonunion and complication rates.<sup>8,9)</sup>

The treatment options may have to be individualized based on the fracture site, displacement and the stability of the prosthesis used, with the classification systems to guide the surgical management. This retrospective study analyses the outcomes of the distal femur periprosthetic fractures following TKA treated by the locked plating.

## METHODS

From 2005 to 2009, 31 patients were admitted with the periprosthetic fractures following a total knee arthroplasty at our institution. All records were retrieved from the hospital's prospectively maintained arthroplasty database. The institutional review board approved the study. Periprosthetic distal femur fractures following a primary TKA treated by the locked plate osteosynthesis were included. Of the 21 patients satisfying the inclusion criteria, 20 patients who consented for the treatment were included in the study. There were 2 type I fractures and 18 type II fractures of the distal femur according to the classification of Rorabeck and Taylor.<sup>10)</sup> The mode of injury was a low-velocity fall in all patients.

The mean age was  $73 \pm 5$  years. Fourteen were female and 6 were male patients. The mean duration between the arthroplasty procedure and the fracture occurrence was  $20.8 \pm 10.4$  months. The mean follow up was  $39 \pm 10$  months.

### Treatment Methods

The lateral vastus splitting approach was used, and the fractures were stabilized with a 4.5 mm precontoured distal femur locked plate (Synthes, Gurgaon, India). If the satisfactory fracture reduction and the limb alignment in the sagittal and the coronal planes could be achieved closed, the minimal access plating technique was used. Failure to achieve a satisfactory reduction necessitated an open approach. The patients were kept non-weight-bearing after the surgery and progressed to full weight-bearing with the fracture consolidation. The range of motion exercises were encouraged immediately post-surgery to minimize motion loss.

### Risk Factors

Osteoporosis (T score  $> -2.5$ ) was evident in 13 patients. The bone quality was graded as osteopenia (T score, between  $-1$  and  $-2.5$ ) in the remaining 7 patients. Other risk factors included a grade II notching of the anterior femoral cortex in 1 patient.

### Statistics

Continuous variables were expressed as mean and standard deviation. Categorical variables were presented as absolute and relative frequencies. The prefracture and follow-up functional outcome measures (Western Ontario and McMaster Universities Arthritis Index [WOMAC], range of motion [ROM]) were compared using Wilcoxon analysis, and the level of significance was set at (2-sided  $p$ -value  $< 0.05$ ).

## RESULTS

Refer to Table 1 for the patient, fracture demographics and the study outcomes.

### Radiological Outcome

One patient died due to an unrelated illness and was lost to follow-up. Nineteen patients were available for the final analysis. Successful osseous union was achieved in 16 patients (84%) at the mean time of  $22 \pm 5$  weeks (Fig. 1). The delay in union (lack of satisfactory progression at 4 months) was seen in 3 patients and was expedited with the iliac crest grafting. Union was ultimately achieved in 2 of the 3 patients by 8 months. Nonunion was diagnosed after a failed grafting in 1 patient (5%) with a deficient bone stock after 8 months (Fig. 2). She ultimately underwent a revision arthroplasty 11 months after the fracture. No patient had a significant deformity in the coronal or sagittal plane ( $> 10^\circ$ ) postsurgery.

### Functional Outcome

The mean range of motion significantly decreased to  $106^\circ \pm 12.8^\circ$  at the last follow up compared to  $125^\circ \pm 9.1^\circ$  before the fracture occurrence ( $p = 0.00$ ). A similar trend was seen in the WOMAC scores, which decreased to  $75.8 \pm 4.2$  compared to the prefracture score of  $84 \pm 3$  ( $p = 0.00$ ). At the last follow-up, 8 patients (42%) were community ambulant without support; 8 (42%) were community ambulant with the assistive aids; and 3 (16%) were restricted to home activities. At the last follow-up, 7 patients were fully satisfied with the outcome; 9 patients were somewhat satisfied; and 3 patients were not satisfied.

### Complications

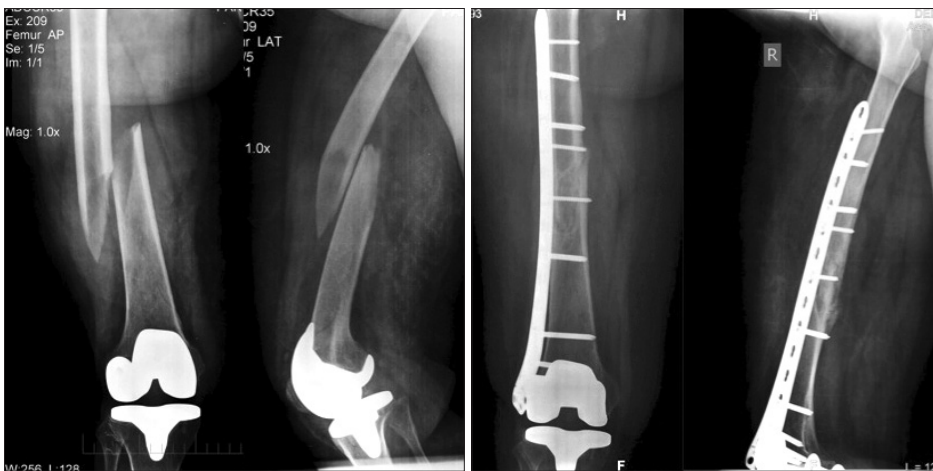For the complications, six secondary procedures were carried out in 5 (26%) patients; the autologous iliac crest grafting in 3 patients; revision arthroplasty in 1 patient; and the knee manipulation under anesthesia in 2 patients after the fracture union to improve ROM. No deep infections were seen. None of the patients died in the early postoperative period ( $< 1$  month). One patient developed

**Table 1.** Summary of Study Data

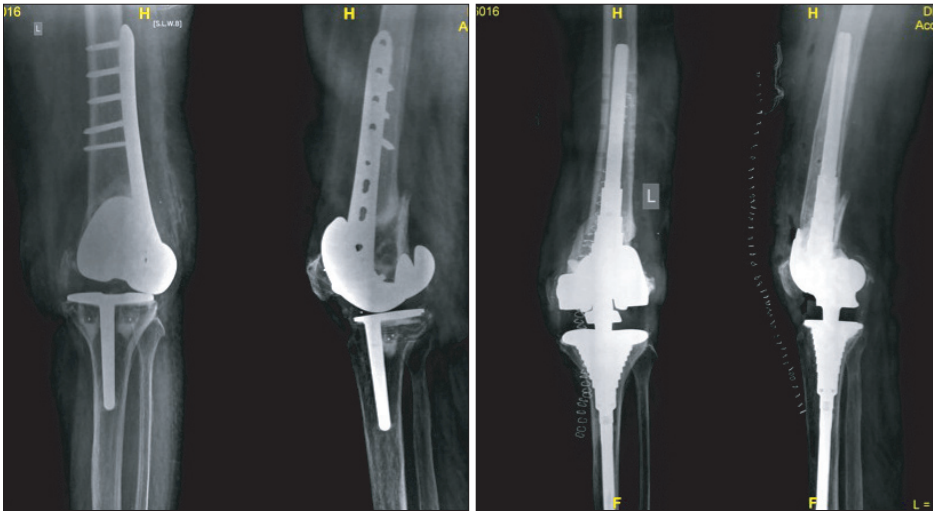
Age/sex	Interval between TKA and fracture* (mo)	Union time (wk)	Follow-up (mo)	ROM (degree)		WOMAC		Complications/remaks
				Prefracture	Follow-up	Prefracture	Follow-up	
75/F	25	16	36	125	110	85.6	79.3	
78/M	30	22	28	135	100	86.4	78.8	
66/F	8	30	48	135	105	87.9	74.2	Delayed union/bone grafting
82/F	48	20	25	120	110	80.3	73.5	
68/M	23	18	33	130	110	81.8	72	
69/F	9	16	52	120	120	87.9	81.6	
80/F	16	24	29	120	100	84.1	75	
75/M	14	23	57	115	120	81.8	78.8	
81/F	25	21	30	115	90	84.1	71.2	MUA
69/F	18	34	45	130	100	82.6	73.5	Delayed union/bone grafting
70/M	24	20	29	140	125	87.9	79.3	
68/F	13	18	47	110	100	78.8	67.4	
83/F	35		57	120	90	80.3	75	Nonunion/revision TKA
69/F	7							Lost in follow-up
75/F	13	20	44	125	100	81.8	75	
72/F	20	24	38	145	140	88.6	82.6	
67/M	27	22	25	130	100	88.6	79.3	
68/F	10	21	33	110	90	79.5	68.2	
70/M	19	20	46	135	100	85.6	77.5	MUA
71/F	35	18	55	120	90	82.6	75	

\*Fracture site: distal femur.

TKA: total knee arthroplasty, ROM: range of motion, WOMAC: Western Ontario and McMaster Universities Arthritis Index, MUA: manipulation under anesthesia.



**Fig. 1.** A type II distal femur fracture treated by minimally invasive plate osteosynthesis (MIPO) using a 4.5 mm distal femur locked plate. Follow-up radiographs show union and satisfactory alignment.



**Fig. 2.** Nonunion of a type II distal femur fracture revised with a constrained total knee arthroplasty due to distal femur bone loss and the resultant instability.

basal atelectasis and a collapsed lung, and 1 patient developed acute renal failure in the perioperative period. Both patients recovered uneventfully.

## DISCUSSION

Distal femur is the most common site for the periprosthetic fracture following TKA. The reported fracture risks following a primary TKA is 0.6% compared to 1.7% for a revision TKA.<sup>11)</sup> The goal of the management is to return the patient to the preinjury activity levels as early as possible. The surgical treatment is currently favored with the improvements in the implant design and surgical techniques. Conservative treatments may be associated with high rates of malunion, pain and stiffness. As such, such treatments should be reserved for the stable fractures in the low-demand and co-morbid individuals.<sup>12)</sup>

The locked plating and retrograde nailing are the currently favored techniques in treating the periprosthetic distal femur fractures. Several authors have reported successful results with the retrograde nailing.<sup>13,14)</sup> The technique is minimally invasive and biological but with a high incidence of malalignment, and the lesser union rates have been reported by some authors. Chettiar et al.<sup>15)</sup> reported the successful union in all 13 patients treated by the retrograde nailing in their study, though the axial malalignments in either the coronal or the sagittal plane (> 5 degrees) were seen in 30% of the patients. Similarly, Large et al.<sup>16)</sup> reported either a nonunion or malunion in all 7 patients treated with the retrograde nailing in their series.

Significant coronal malalignments were not seen in our study. Rotational alignment is difficult to appreciate intraoperatively. We compared the position of the lesser trochanter with the opposite limb to roughly establish the right

rotation.<sup>17)</sup> The rotation of the hip was also compared with the opposite hip after fixation. While several methods have been described to assess the rotational alignment during the surgery, none of the methods are reliable. The rotational malalignments, though less common, have been described with the plating, especially with the minimal access techniques.<sup>18)</sup>

The locked plating can be minimally invasive, and the successful healing rates have been reported even in the osteoporotic bones with the lesser incidence of malalignment.<sup>19,20)</sup> Most of the fractures in our study were treated with the minimal access locked plating, which preserved the fracture biology and minimized the muscle damage. Despite the limitations in the bone quality, we were able to achieve the satisfactory union rates. The study outcomes in terms of the union rate, function and incidence of complications were comparable to the previously published studies.<sup>21,22)</sup> Osteoporosis is a major determinant in the fracture occurrence following arthroplasty.<sup>23)</sup> It can also complicate the fixation strategies and delay rehabilitation. Sixty-five percent of the patients in the current study suffered the osteoporotic insufficiency fracture. Long-term medical management of osteoporosis may be justified after the arthroplasty procedure, especially in females.

Despite the satisfactory rate of union with an acceptable complication rate, only around 45% of the patients were fully satisfied with the treatment and were able to return to the pre-fracture activity levels. There was a significant drop in the functional level as evident from the WOMAC scores and the range of motion analysis. Additional risk factors including osteoporosis, increasing age and medical co-morbidities can prolong rehabilitation and may contribute to the deterioration in function. The retrospective analysis, a relatively small sample size and the short follow-up are the limitations of this study.

All data used in the study were collected from a prospectively maintained arthroplasty database. In conclusion, an acceptable to satisfactory clinical results can be achieved with the locked plate osteosynthesis for the periprosthetic distal femur fractures following TKA.

## CONFLICT OF INTEREST

No potential conflict of interest relevant to this article was reported.

## REFERENCES

- Berry DJ. Epidemiology: hip and knee. *Orthop Clin North Am.* 1999;30(2):183-90.
- Hohl M. Fractures about the knee. In: Rockwood CA, Green DP, eds. *Fractures in adults.* 2nd ed. Philadelphia: JB Lippincott; 1984. 1429-44.
- Merkel KD, Johnson EW Jr. Supracondylar fracture of the femur after total knee arthroplasty. *J Bone Joint Surg Am.* 1986;68(1):29-43.
- McAuley JP, Sanchez FL. Knee: role and results of allografts. *Orthop Clin North Am.* 1999;30(2):293-303.
- Moran MC, Brick GW, Sledge CB, Dysart SH, Chien EP. Supracondylar femoral fracture following total knee arthroplasty. *Clin Orthop Relat Res.* 1996;(324):196-209.
- Felix NA, Stuart MJ, Hanssen AD. Periprosthetic fractures of the tibia associated with total knee arthroplasty. *Clin Orthop Relat Res.* 1997;(345):113-24.
- Chalidis BE, Tsiroidis E, Tragas AA, Stavrou Z, Giannoudis PV. Management of periprosthetic patellar fractures. A systematic review of literature. *Injury.* 2007;38(6):714-24.
- Chen F, Mont MA, Bachner RS. Management of ipsilateral supracondylar femur fractures following total knee arthroplasty. *J Arthroplasty.* 1994;9(5):521-6.
- Herrera DA, Kregor PJ, Cole PA, Levy BA, Jonsson A, Zlozdowski M. Treatment of acute distal femur fractures above a total knee arthroplasty: systematic review of 415 cases (1981-2006). *Acta Orthop.* 2008;79(1):22-7.
- Rorabeck CH, Taylor JW. Classification of periprosthetic fractures complicating total knee arthroplasty. *Orthop Clin North Am.* 1999;30(2):209-14.
- Meek RM, Norwood T, Smith R, Brenkel IJ, Howie CR. The risk of peri-prosthetic fracture after primary and revision total hip and knee replacement. *J Bone Joint Surg Br.* 2011;93(1):96-101.
- Culp RW, Schmidt RG, Hanks G, Mak A, Esterhai JL Jr, Heppenstall RB. Supracondylar fracture of the femur following prosthetic knee arthroplasty. *Clin Orthop Relat Res.* 1987;(222):212-22.
- Gliatis J, Megas P, Panagiotopoulos E, Lambiris E. Midterm results of treatment with a retrograde nail for supracondylar periprosthetic fractures of the femur following total knee arthroplasty. *J Orthop Trauma.* 2005;19(3):164-70.
- Han HS, Oh KW, Kang SB. Retrograde intramedullary nailing for periprosthetic supracondylar fractures of the femur after total knee arthroplasty. *Clin Orthop Surg.* 2009;1(4):201-6.
- Chettiar K, Jackson MP, Brewin J, Dass D, Butler-Manuel PA. Supracondylar periprosthetic femoral fractures following total knee arthroplasty: treatment with a retrograde intramedullary nail. *Int Orthop.* 2009;33(4):981-5.
- Large TM, Kellam JF, Bosse MJ, Sims SH, Althausen P, Masonis JL. Locked plating of supracondylar periprosthetic femur fractures. *J Arthroplasty.* 2008;23(6 Suppl 1):115-20.
- Kim JJ, Kim E, Kim KY. Predicting the rotationally neutral state of the femur by comparing the shape of the contralateral lesser trochanter. *Orthopedics.* 2001;24(11):1069-70.
- Buckley R, Mohanty K, Malish D. Lower limb malrotation following MIPO technique of distal femoral and proximal tibial fractures. *Injury.* 2011;42(2):194-9.
- Kolb W, Guhlmann H, Windisch C, Marx F, Koller H, Kolb K. Fixation of periprosthetic femur fractures above total knee arthroplasty with the less invasive stabilization system: a midterm follow-up study. *J Trauma.* 2010;69(3):670-6.
- Streubel PN, Gardner MJ, Morshed S, Collinge CA, Gallagher B, Ricci WM. Are extreme distal periprosthetic supracondylar fractures of the femur too distal to fix using a lateral locked plate? *J Bone Joint Surg Br.* 2010;92(4):527-34.
- Hou Z, Bowen TR, Irgit K, et al. Locked plating of periprosthetic femur fractures above total knee arthroplasty. *J Orthop Trauma.* 2012;26(7):427-32.
- Ricci WM, Loftus T, Cox C, Borrelli J. Locked plates combined with minimally invasive insertion technique for the treatment of periprosthetic supracondylar femur fractures above a total knee arthroplasty. *J Orthop Trauma.* 2006;20(3):190-6.
- Sisto DJ, Lachiewicz PF, Insall JN. Treatment of supracondylar fractures following prosthetic arthroplasty of the knee. *Clin Orthop Relat Res.* 1985;(196):265-72.