




Contents lists available at ScienceDirect

Injury

journal homepage: www.elsevier.com/locate/injury

A load-sharing nail - cage construct may improve outcome after induced membrane technique for segmental tibial defects

Ashok S Gavaskar*, S. Parthasarathy, J. Balamurugan, Rufus V Raj, Vijay S Chander, L.K. Ananthkrishnan

Rela Institute of Orthopedics, Dr. Rela Institute & Medical Centre, Chennai, India

ARTICLE INFO

Article history:

Accepted 21 November 2019

Available online xxx

Keywords:

Induced membrane technique

Masquelet technique

Bone loss

Infected gap nonunion

Open fractures

Titanium cage

ABSTRACT

Introduction: Induced membrane technique (IMT) is a well-established technique for treating segmental bone defects. Different variations of the technique have been described. Our objective was to evaluate radiological and functional outcome with IMT using a nail - graft filled titanium cage construct for segmental traumatic bone defects of the tibia.

Patients and methods: 26 adult patients with moderate (> 5 cm) or large (> 10 cm) segmental tibial defects after acute open fractures or implant related infected nonunions underwent the procedure. The technique involved 2 stages. After standard debridement +/- implant removal and application of an antibiotic loaded cement spacer in stage 1, the second stage included placement of an intramedullary nail across the defect and an impacted graft filled titanium mesh cage was used to reconstruct the bone defect. Radiographic evidence of bony union, time to painless un-assisted weight bearing, return to work and functional evaluation with lower extremity functional scale (LEFS) were assessed.

Results: 5/26 cases were excluded due to failure in controlling infection. 100% union rates were achieved in the remaining 21 patients. 2 patients (9.5%) required repeat bone grafting. The mean time to painless un-assisted painless weight bearing was 26 ± 9.2 days and the mean time to return to work was 45 ± 12.5 days. The mean LEFS at a mean follow up of 27 months was 67 ± 4.7 .

Conclusions: Excellent union rates with good functional restoration can be achieved after IMT using the nail - cage construct for segmental tibial defects. Persistent infection is the biggest impediment for successful execution of the technique. Addition of a cage may also improve short-term functional outcome in terms of ability to weight bear and early return to work.

© 2019 Elsevier Ltd. All rights reserved.

Introduction

Induced membrane technique (IMT) described by Alain Charles Masquelet has gained popularity and widespread acceptance for dealing with segmental bone defects over the last decade [1]. The two-stage method has emerged as a reliable alternative to bone transport techniques. Originally described for aseptic long bone defects, the method involves debridement of the defect, implantation of a polymethylmethacrylate (PMMA) spacer and external fixation in stage 1. In stage 2, 6 - 8 weeks later the spacer is removed with preservation of the membrane, bone grafting is done within the confines of the membrane and external fixation is continued [2]. Over a period of time, lot of modifications and improvisations has

been described to the original technique. These include expanding the indications to cover septic conditions, addition of antibiotics to the PMMA cement, more widespread use of internal fixation and use of allograft and synthetic bone graft alternatives [3-6]. It is true that the use of internal fixation (Intramedullary nails/ plates) has helped in greater mobility and avoids problems with external fixation. However patients are often kept on protected weight bearing for a lengthy period of time especially with larger defects in order to protect the internal fixation from failure. To overcome this problem, we started using titanium mesh cages in combination with intramedullary (IM) nails to create a load sharing construct thereby enabling patients to weight bear as tolerated post surgery. First described by Cobos [7] and colleagues, there are only a few case reports on the use of titanium cages in traumatic reconstructions. In this manuscript, we describe our experience with IMT in a cohort of patients with post - traumatic tibial segmental defects using the nail - cage construct. Our objective was to study

* Corresponding author: Rela Institute of Orthopedics, Dr. Rela Institute & Medical Centre, 7, CLC works road, Chromepet, Chennai 600044, TN, India.
E-mail address: gavaskar.ortho@gmail.com (A.S. Gavaskar).

<https://doi.org/10.1016/j.injury.2019.11.031>

0020-1383/© 2019 Elsevier Ltd. All rights reserved.

Table 1
Patient details.

Age	36 ± 11
Sex	
Males	15
Females	6
Defect type:	
Acute bone loss	8
Implant related infection/nonunion	13
Defect size:	
Moderate (5–10 cm)	15
Large (10–15 cm)	6

the effects of adding a titanium mesh cage in terms of radiological and functional outcome.

Materials and methods

The study was conducted in a prospective manner at a tertiary care institution from September 2014 - March 2017. We aimed for a cohort of 20 patients to derive reasonable conclusions from the study. We had a total of 29 eligible patients during the study period. 3 patients were excluded for not willing to be a part of the study. The final cohort of 26 was arrived at on basis of availability of patients within the study period and to account for loss in follow-up. No formal sample size calculations were performed. Informed consent was obtained from all patients and the institutional review board (IRB) approved the study. 26 patients with moderate (> 5 cm) and large (> 10 mm) segmental tibial bone defects were included in the study. Both acute traumatic defects after open fractures and defects post debridement for implant related infection and nonunion were included. Patients with segmental bone loss less than 5 cm were excluded. Smokers, patients with uncontrolled diabetes and peripheral vascular disease were excluded. Details of patients and their defect patterns are described in (Table 1). Following surgery, all data were collected in a prospective manner during follow up visits. For final assessment, a minimum of 18 months follow up was prescribed. The final follow up analysis was done between October 2018 and December 2018.

Surgical technique

Stage 1

The length of the normal side tibia using two proximal and distal bony points was measured before the start of surgery under fluoroscopy to serve as reference for length restoration. After debridement of the defect till active bleeding edges (Paprika sign) or removing bone fragments that lack soft tissue attachments, the defect was brought out to length using a distractor. In cases with IM nail related infections, the medullary cavity was debrided using the reamer irrigator aspirator (RIA, Synthes - India). External fixation using a monopolar fixator was performed next to maintain length and alignment. The PMMA spacer (PALACOS) was prepared with addition of vancomycin powder (2 g/ 40 gm of cement) and implanted in the late doughy phase. Care was taken to make sure the cement spacer extends beyond the edges of the defect. Soft tissue cover was provided either with primary closure or a flap depending on the situation.

Stage 2

Stage 2 was performed after 4–10 weeks once the C - reactive protein (CRP) level had hit baseline and the soft tissues had healed adequately. The PMMA spacer is carefully removed preserving the integrity of the induced membrane. The defect length is

measured and the external fixator is removed. The medullary cavity is reamed and interlocking nail of size 1.5 mm less than the last reamer was chosen for fixation. A lumbar spine titanium cylindrical mesh cage (GESCO surgicals, India) of the same length as the defect is chosen to create a load-sharing construct. The inner diameter of the cage should be at least 5 mm more than the nail diameter to allow space for the graft. It should also closely engage the cortices on the both sides of the defect. Autografts harvested either from the iliac crests or femur using the RIA was used. RIA grafts if used was always combined with iliac crest grafts to improve porosity. The graft was impacted in layers in to the cage until a solid tube of graft filled cage is created. A 3.2 mm guide pin is drilled through the middle of the graft. The graft is serially reamed over the guide pin starting with a 8.5 mm end cutting reamer. Progressive reaming is continued till the channel is reamed 1 mm more than the chosen nail diameter. This compacts the cancellous grafts in the periphery of the cage with a central channel for the nail to pass through (Fig. 1).

The defect is cleansed, remaining cancellous graft is placed posteriorly and the defect is over - distracted using a distractor to facilitate cage insertion. The long flexible guide wire is inserted and then carefully guided across the defect through the central track of the graft filled cage. The nail is then carefully threaded over the guide wire gently with toggling motion till it is completely seated. The distractor is released and the defect is compressed to make sure the cage engages the cortices on both sides. The nail is then locked on both sides in static mode. The membrane is carefully closed after loosely packing the remaining grafts. Post surgery, patients were allowed to walk weight bearing as tolerated with or without assistance.

Patients with implant related infections were initially kept on broad-spectrum antibiotics followed by culture specific antibiotics till 3 days after completion of stage 2. A standard antibiotic policy using a combination of II generation cephalosporin + aminoglycoside for 3 days was used for patients with acute open fractures during both stages. No prophylaxis was used for preventing deep vein thrombosis (DVT).

Patients were first reviewed at 6 weeks after the second stage of IMT, then every 6 weeks till radiological consolidation of the defect. X-rays were performed during outpatient visits to assess bony consolidation of the defect. Time to defect consolidation as evident by bridging bone across a minimum of three cortices was assessed. Time to weight bear independently without support and time to return to work were recorded to assess early functional recovery. Functional outcome evaluation at last follow up was performed using the lower extremity functional scale (LEFS). Complications and failures were recorded. Trainees and radiologists who were blinded to the study outcome performed all radiological and functional evaluations.

Statistical analysis

Statistical data analysis was performed using Statplus (version v6). All analyzed data were continuously distributed data and were expressed as mean and standard deviation. The level of significance was set at $P < 0.05$. Subgroup analysis using independent T test was used to identify differences in outcome and complications between patients with acute defects vs infected nonunion and patients with moderate vs large defects.

Results

3 patients had a failed stage 1 due to persistent infection and hence were excluded. 2 patients developed recurrence of infection after stage 2. In these 5 patients with lack of infection control

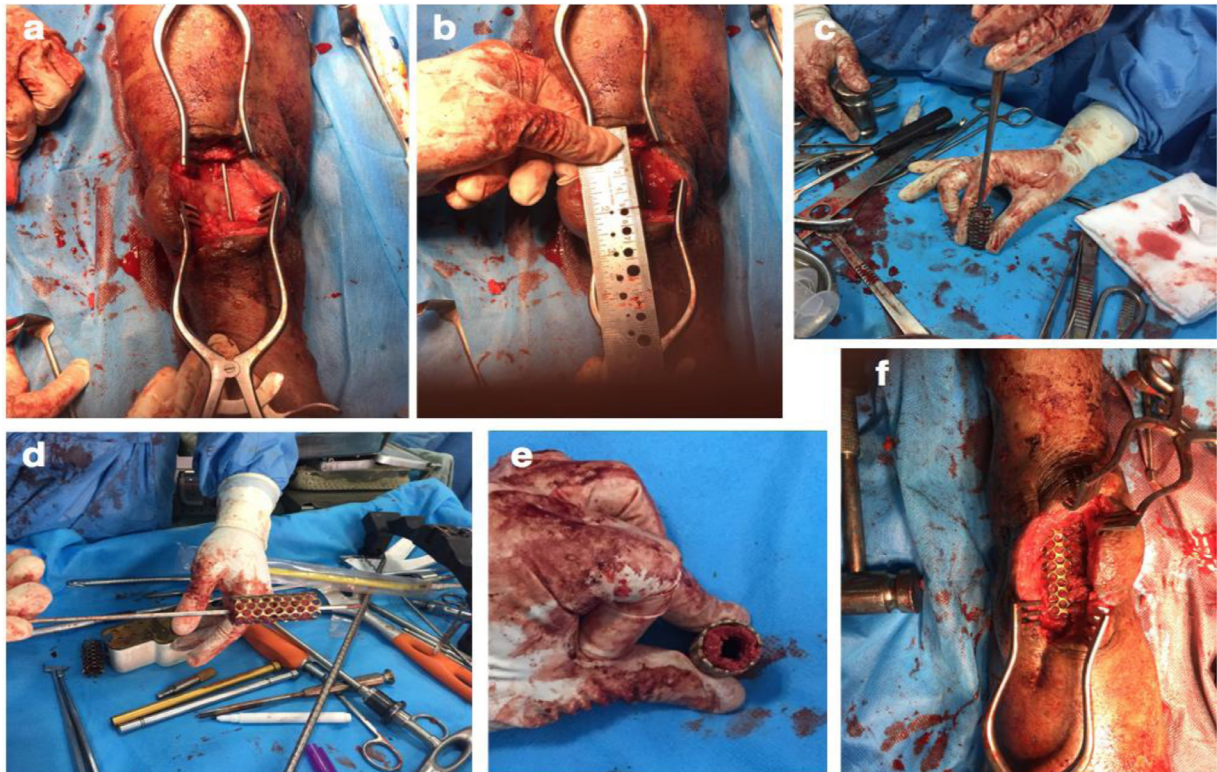


Fig 1. Steps of creating a nail and impacted graft filled cage construct across the defect.

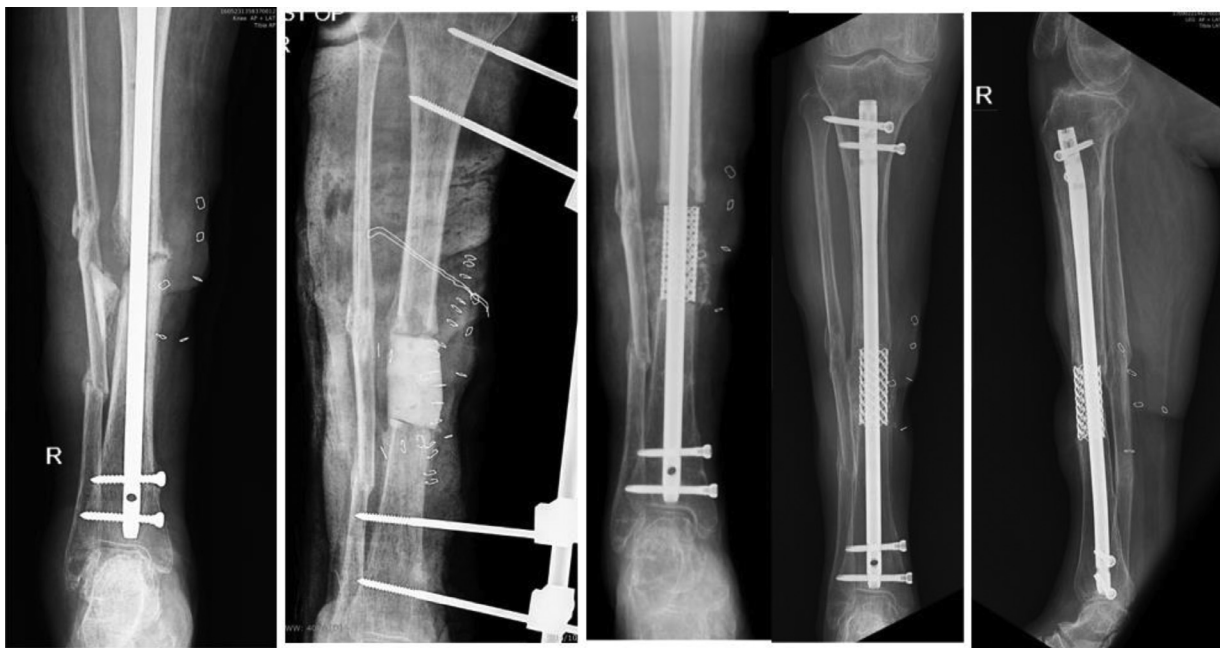

Fig 2. Infected nonunion after IM nailing in a 60 years female. Resection & reconstruction of 6 cm defect with cage assisted IMT. Radiological union was evident at 4.5 months.

or recurrence, resection and bone transport with ring fixator was performed and were excluded from the study. Remaining 21 patients were available for follow up through the entire study period and were included for the final analysis. The mean follow up was 27 ± 6.8 months. The mean size of the defect was 8.4 ± 2.3 cm. The mean time between stage 1 and 2 was 46.5 ± 9.6 days. The wound was closed primarily in 7 patients. A flap cover was required in 14 patients. Bone grafts were harvested from either one

or both iliac crests in 15 patients. In 6 patients, RIA grafts were combined with grafts from one iliac crest. Radiological union was achieved in all patients (Figs. 2 & 3). Mean time to weight bear without pain & assistance was 26 ± 9.2 days. Mean time for radiological consolidation of the defect was 169 ± 33 days. Mean time to return to work was 45 ± 12.5 days (videos 1 & 2 – supplemental content). The mean LEFS score at a mean follow up of 27 months was 67 ± 4.7 .

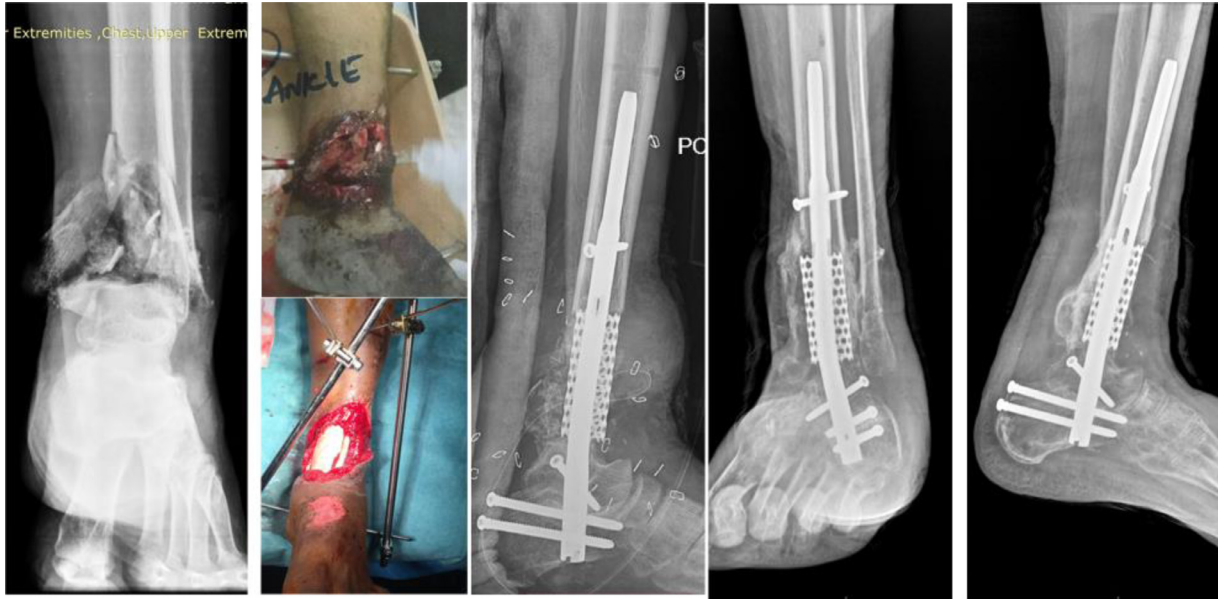

Fig 3. Grade IIIIB open fracture with articular and metaphyseal bone loss in a 33 years male. Reconstruction of a 10 cm defect using cage assisted IMT. Radiological union was evident at 6 months.

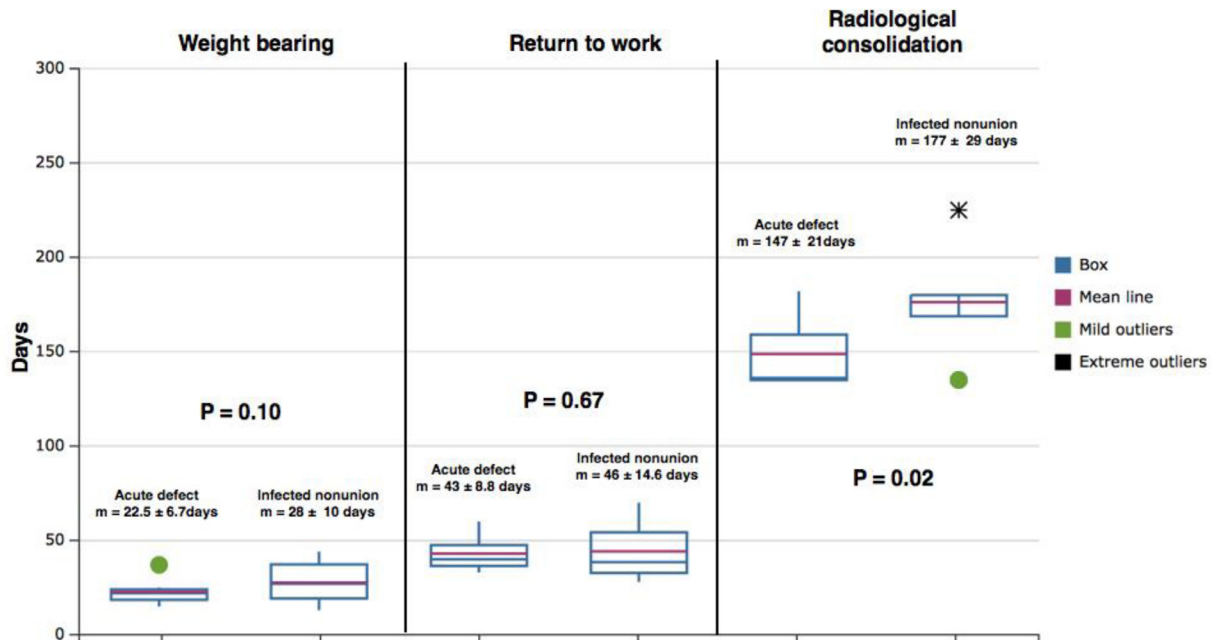


Fig 4. Box plots showing the difference between patients with acute defects and infected nonunion in terms of weight bearing, return to work and time for radiological consolidation.

Subgroup analysis

Implant related infected nonunions vs acute traumatic defects (Fig. 4):

Patients with implant related infected nonunion required significantly more time between stage 1 and 2 compared to acute defects ($P < 0.01$). Union rates and LEFS scores at final follow up were similar in both groups. Time to painless un-assisted weight bearing and time to return to work were similar in both groups. Radiological consolidation took a significantly longer time in patients with infected nonunion ($P = 0.02$). All 5 patients who were excluded due to persistent infection either after stage 1 or 2 had an infected nonunion.

Moderate vs large defects (Fig. 5):

Union rates and LEFS scores at final follow up were similar in both groups. Time for radiological consolidation ($P < 0.01$), time to un-assisted painless weight bearing ($P = 0.02$) and return to work ($P = 0.08$) were significantly longer in patients with large defects. Graft site pain was significantly more in patients with large defects ($P < 0.01$).

Complications

Graft site pain was the most common complication seen in 7 (30%) patients. Bowel herniation was seen in 1 patient post iliac crest grafting and was repaired. A symptomatic proximal DVT was seen in 1 patient post reconstruction and was managed appropriately. Flap necrosis was seen in one patient after stage 1 and

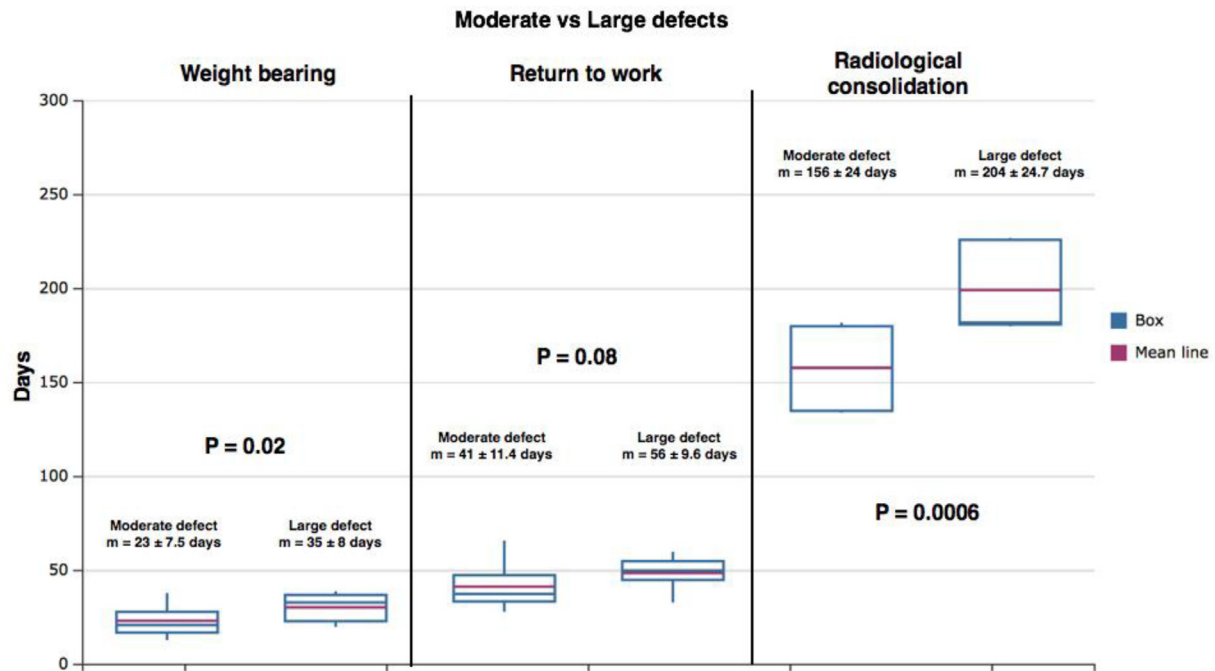


Fig 5. Box plots showing the difference between patients with moderate and large defects in terms of weight bearing, return to work and time for radiological consolidation.

had to undergo a repeat free flap and re-implantation of a new PMMA spacer before successfully progressing to stage 2. Repeat bone grafting was required in 2 patients to address delay in radiological consolidation on one side of the defect.

Discussion

Dealing with moderate to large segmental defects in tibia represents a huge surgical challenge [8]. Often these patients require multiple surgeries to deal with bone and soft tissue defects. Presence of infection complicates the scenario and compromises the possibility of achieving a favorable outcome. Bone transport or lengthening using external fixators has shown good results and often the technique of choice for managing these patients. This technique requires retaining of external fixators for a long time with issues of compliance, pain, pin track infections and docking site problems [9].

IMT was described as a method to bridge large segmental defects. The technique gained popularity and has been extensively modified to optimally deal with bone defects. The success rates of IMT is equivalent to bone transport using Ilizarov fixator, but IMT is more popular because of better patient compliance and uses familiar techniques and implants from the surgeon's perspective [10,11]. Compared to the Ilizarov fixator, when IMT is used for bridging large defects, patients are placed on a protected weight bearing protocol for a longer period of time [12], since the IM nail or plate lacks the rigidity and stiffness of the multiplanar tensioned fine wire fixator. This compromises the patient's ability to return to work early and delays functional and vocational rehabilitation.

The use of interpositional cages in bone defects was first described by Cobos and colleagues, since then multiple case reports have been published on the technique [13,14]. Use of an additional mesh cage restores osseous continuity across the ends of the defect. This allows safe transmission of loads across the defect with weight bearing even during the early phase of treatment. The IM nail - cage combination allows creation of a load-sharing construct with the nail along the axis of the long bone. This provides ex-

cellent stability, optimal loading of the bone and protects the IM nail from axial and bending loads [15,16]. As evident from the results, the functional recovery was rapid with patients weight bearing without pain and support at a mean of 26 days and was able to return to work at a mean of 45 days.

Recent evidence shows that the results of IMT are not consistent for tibial defects [17]. Most of the unfavorable results reported are due to persistent or recurrence of infection. As Masquelet pointed out, IMT is meant for reconstruction of bone defects and infection has to be controlled before skeletal reconstruction [18]. On this basis, we excluded 5 patients; 3 after failed first stage and 2 after a failed second stage surgery due to persistent infection and did not consider them failures of the IMT. Strict inclusion criteria, performing the second stage surgery with a delay of up to 10 weeks, addition of the cage to improve stability and more liberal use of free flaps to provide a healthy soft tissue cover and vascularity to the nonunion site may also be possible explanations for the good outcome. Providing a good vascular soft tissue cover is considered important for perfusion of the grafts [19].

From a biological standpoint too, the cage has several advantages. The combination of a biocompatible titanium mesh cage filled with autografts provides an optimal environment healing of large defects. The cage contains the graft acting as a barrier and the mesh design allows it to act as an excellent scaffold for permitting ingrowth of vascular channels and promoting new bone formation [20]. Typically new bone growth can be seen inside and outside the cage leading to rapid consolidation of the defect. After a successful stage 2 surgery, 100% patients ultimately achieved radiological union with only 2 (9.5%) patients requiring additional bone grafting.

Graft choices for reconstruction is crucial for good outcome. We still prefer autografts from the iliac crest. Harvesting grafts from long bone is an option using the (RIA) reamer irrigator aspirator. The RIA grafts however lack porosity and has poor scaffolding properties [21]. RIA grafts can be combined with iliac grafts to improve osteoinductive properties of the RIA graft and to limit graft site morbidity at the iliac crest. Use of allografts and synthetic

bone substitutes can be used in combination with autografts since stand-alone usage may compromise consolidation and osteointegration [22].

The study has several limitations. The sample size was small, short duration of follow up and there was no control group to validate the hypothesis. A bigger sample is difficult given the prevalence of the problem. We aimed to study the short-term advantages of using a cage - nail construct; hence a longer follow up was not required. It is also difficult to assess radiological evidence of bone union using x-rays in these patients and in cases of doubt CT scans may be better compared to conventional x-rays. Occurrence of late implant failures has been previously reported in similar cases in the absence of bony consolidation. The most common criticism for the use of a cage stems from the fact that the cage becomes incorporated in new bone and cannot be removed without damaging the bone. While this may be less of a problem in cases of early occurrence or recurrence of infection where the cage can be easily removed as was done in 2 failed cases, safe removal of the cage for whatever reason after osseous consolidation of the defect is extremely difficult without bone resection. Recent articles have shown favorable results with regards to recurrence of infection once bony consolidation has been achieved [23]. The only way to overcome the problem however, would be to use bio-absorbable cages which will provide strength and stability post surgery and will resorb over a period 6 - 12 months. This is definitely within the scope of nanotechnology and we may see use of bio-absorbable cages in future. As of now, careful use in select indications and ruling out infection or completely eradicating infection before using the cage - nail construct is recommended. To conclude, use of a nail - cage construct gives excellent radiological and functional results after IMT in patients with acute defects and infective nonunions. Infection is the impediment for good results and has to be eradicated before bony reconstruction. The technique does not require a long learning curve and reproducible results can be achieved without additional complications.

I, the corresponding author hereby affirm that none of the authors have any potential conflicts of interest.

Declaration of Competing Interest

I, the corresponding author assure that there were no potential conflicts of interest involved with any of the authors involved in the study. Authors declare no conflict of interest . No external funding was received for the study

Supplementary materials

Supplementary material associated with this article can be found, in the online version, at [doi:10.1016/j.injury.2019.11.031](https://doi.org/10.1016/j.injury.2019.11.031).

References

- [1] Masquelet AC, Fitoussi F, Begue T, et al. Reconstruction of long bones by the induced membrane and spongy autograft [in French]. *Ann Chir Plast Esthet* 2000;45:346-53.
- [2] Masquelet AC, Begue T. The concept of induced membrane for reconstruction of long bone defects. *Orthop Clin North Am* 2010;41:27-37.
- [3] Aparid T, Bigorre N, Cronier P, et al. Two-stage reconstruction of post-traumatic segmental tibia bone loss with nailing. *Orthop Traumatol Surg Res* 2010;100:194-8.
- [4] Flamans B, Pauchot J, Petite H, et al. Use of the induced membrane technique for the treatment of bone defects in the hand or wrist, in emergency. *Chir Main* 2010;29(5):307-14.
- [5] Gunepin FX, Laine P, Nuzzaci F, et al. Use of the induced membrane technique for the management of chronic osteomyelitis of the humerus in an adolescent in a precarious environment for surgery. *J Bone Joint Surg Br* 2008;90(Suppl. II):248.
- [6] Stafford PR, Norris BL. Reamer-irrigator-aspirator bone graft and bi Masquelet technique for segmental bone defect nonunions: a review of 25 cases. *Injury* 2010;41(Suppl. 2):S72-7.
- [7] Cobos J, Lindsey RW, Gugala Z. The cylindrical titanium mesh cage for the treatment of a long bone defect: description of a new technique and report of two cases. *J Orthop Trauma* 2000;14:54-9.
- [8] Nauth A, McKee MD, Einhorn TA, et al. Managing bone defects. *J Orthop Trauma* 2011;25:462-6.
- [9] Dahl MT, Gulli B, Berg T. Complications of limb lengthening. A learning curve. *Clin Orthop Relat Res* 1994;301:10-18.
- [10] Morelli I, Drago L, George DA, et al. Masquelet technique: myth or reality? A systematic review and meta-analysis. *Injury* 2016;47(suppl 6):S68-76.
- [11] Ristiniemi J, Lakovaara M, Flinkkilä T, et al. Staged method using antibiotic beads and subsequent autografting for large traumatic tibial bone loss: 22 of 23 fractures healed after 5-20 months. *Acta Orthop* 2007;78:520-7.
- [12] Woon CY, Chong KW, Wong MK. Induced membranes-a staged technique of bone-grafting for segmental bone loss: a report of two cases and a literature review. *J Bone Joint Surg Am* 2010;92(1):196-201 Jan. doi:10.2106/JBJS.1.00273.
- [13] Ostermann PA, Haase N, Rubberdt A, Wich M, Ekkernkamp A. Management of a long segmental defect at the proximal meta-diaphyseal junction of the tibia using a cylindrical titanium mesh cage. *J Orthop Trauma* 2002;16:597-601.
- [14] Attias N, Lehman RE, Bodell LS, Lindsey RW. Surgical management of a long segmental defect of the humerus using a cylindrical titanium mesh cage and plates: a case report. *J Orthop Trauma* 2005;19:211-16.
- [15] Attias N, Lindsey RW. Case reports: management of large segmental tibial defects using a cylindrical mesh cage. *Clin Orthop Relat Res* 2006;450:259-66.
- [16] Morwood MP, Streufert BD, Bauer A, et al. Intramedullary nails yield superior results compared to plate fixation when using the Masquelet technique in the femur and tibia. *J Orthop Trauma* 2019;33(11):547-52.
- [17] Morris R, Hossain M, Evans A, Pallister I. Induced membrane technique for treating tibial defects gives mixed results. *Bone Joint J* 2017;99-B:680-5.
- [18] Masquelet AC. Induced membrane technique: pearls and pitfalls. *J Orthop Trauma* 2017;31:S36-8 OctSuppl 5. doi:10.1097/BOT.0000000000000979.
- [19] Gugala Z, Lindsey RW, Gogolewski S. New approaches in the treatment of critical-size segmental defects in long bones. *Macromol Symp* 2007;253:147-61.
- [20] Gianouddis PV, Krettek C, Lowenbeg DW, Tosounidis T, Jr Borelli J. Fracture healing adjuncts—the world's perspective on what works. *J Orthop Trauma* 2018;32(3):S43-7.
- [21] Yee MA, Mead MP, Alford AI, Hak DJ, Mauffrey M, Hake ME. Specific understanding of the induced membrane technique. Current status and future directions. *J Orthop Trauma*. 2017;31(10):S3-8.
- [22] Piacentini F, Ceglie MJ, Bettini L, et al. Induced membrane technique using enriched bone grafts for treatment of posttraumatic segmental long bone defects. *J Orthop Traumatol (Italy)* 2019;20(1):13 11. doi:10.1186/s10195-019-0522-6.
- [23] Masquelet AC, Kishi T, Benko PE. Very long-term results of post-traumatic bone defect reconstruction by the induced membrane technique. *Orthop Traumatol Surg Res* 2019;105(1):159-66.