

Blocking screws: an adjunct to retrograde nailing for distal femoral shaft fractures

Ashok S Gavaskar,¹ Naveen Chowdary²

¹ Parvathy Hospital, Chennai, India

² Global Hospital, Chennai, India

ABSTRACT

Purpose. To review records of 11 patients who underwent retrograde nailing in conjunction with blocking screws to aid fracture reduction for distal femoral shaft fractures.

Methods. Records of 8 men and 3 women aged 27 to 60 (mean, 41) years who underwent retrograde nailing with the use of blocking screws for distal femoral shaft fractures were reviewed. Two of the fractures were open and graded as Gustilo-Anderson grade II. The mean surgical delay was 2 (range, 1–5) days.

Results. All fractures united after a mean of 14 (range, 11–16) weeks without malalignment. There was no screw breakage, screw bending, or wound infection.

Conclusion. Blocking screws increase the stability of the construct and thereby minimise macro-motion at the fracture site.

Key words: bone nails; bone screws; femur; fracture fixation, intramedullary; tibia

INTRODUCTION

Retrograde intramedullary nailing is an established technique for treating distal femoral shaft and supracondylar fractures.¹ Insertion of the nail with a percutaneous technique enables easier reduction of the short distal fragments.² Nonetheless, the reduction is difficult to maintain and the deformity at the fracture site may persist, because of the large space in the distal fragment and the lack of cortical contact with the intramedullary nail.³ Distal femoral shaft fractures tend to become recurvatum in the sagittal plane and result in a valgus deformity in the coronal plane. The use of blocking screws—poller screws—to prevent deformities during nailing has been well reported for proximal tibial fractures,⁴ but rarely for distal femoral fractures. Blocking screws decrease the intramedullary diameter of the metaphysis and act as an artificial cortex to aid fracture reduction.⁵ Blocking screws guide the nail in line with the diaphysis and enable collinear placement of the nail in the proximal and distal fragments. We reviewed records of 11 patients who underwent retrograde nailing in conjunction with the use of blocking screws to aid

fracture reduction for distal femoral shaft fractures.

MATERIALS AND METHODS

From September 2007 to December 2008, 26 patients with distal femoral shaft and supracondylar fractures without intercondylar extension underwent retrograde nailing in our hospital. Records of 8 men and 3 women aged 27 to 60 (mean, 41) years who underwent retrograde nailing in conjunction with blocking screws were reviewed. All surgeries were performed by either of the authors. The causes of injury were high-velocity road traffic accidents (n=9) and falls from a height (n=2). Two of the fractures were open and graded as Gustilo-Anderson grade II. The mean surgical delay was 2 (range, 1–5) days.

Patients were operated on under spinal anaesthesia. They were placed supine on a radiolucent table with the knee flexed to 90° hanging by the edge of the table. The opposite limb was abducted to enable unimpeded access of the image intensifier. A 15 to 20 mm patellar tendon splitting incision was made. The entry point for the guide pin was anterior to the posterior cruciate ligament insertion on the femur, with the knee flexed to 40° to 60°. The guide pin was centred on the intercondylar notch in the anteroposterior plane and at the anterior tip of the Blumensaat intercondylar roof line on the lateral plane when there was no coronal plane deformity.⁶ When there was a valgus (or varus) deformity, the entry point for the guide pin was made on the lateral (or medial) wall of the intercondylar notch.

The proximal expanded portion of the nail was then reamed using a short solid reamer. A long ball tipped guide wire was passed into the distal fragment after fracture reduction. After serial reaming of the medullary cavity, an appropriately sized nail was inserted, in which the distal tip of the nail ended beyond the lesser trochanter. Fracture reduction was assessed using fluoroscopy to determine the need for blocking screws. Blocking screws were placed in the anteroposterior direction to correct any coronal plane deformity and in the mediolateral direction for any sagittal plane deformity. The screws could be placed in the proximal or distal fragments depending on the fracture location. They were placed anterior to the nail when the distal fragment was flexed, medial to the nail for a valgus deformity, and lateral to the nail for a varus deformity (Fig. 1).

In case of persistent flexion of the distal fragment, a 4.9-mm locking bolt from the same nailing set was inserted anterior to the desired nail passage. An anterior screw displaced the nail posteriorly in the

distal fragment and corrected the flexion deformity as the nail entered the proximal fragment. The site for screw placement was identified with the nail *in situ*; space should be available for the nail to correct the deformity posteriorly. The anterior screw had to have intact contact with the nail to act as a cortex. After identifying the site, the nail was removed leaving the guide wire inside. The track for the screw was then drilled and an appropriately sized screw with bicortical purchase was inserted. The desired nail passage was reamed again to ensure that the reamer contacted the blocking screw without impediment. If the blocking screw impeded the reamer, a smaller reamer was used and gradually upsized to widen the canal. Alternatively, a rigid cannulated reamer was used with a gentle axial force to create the offset track. If these methods failed, the blocking screw would

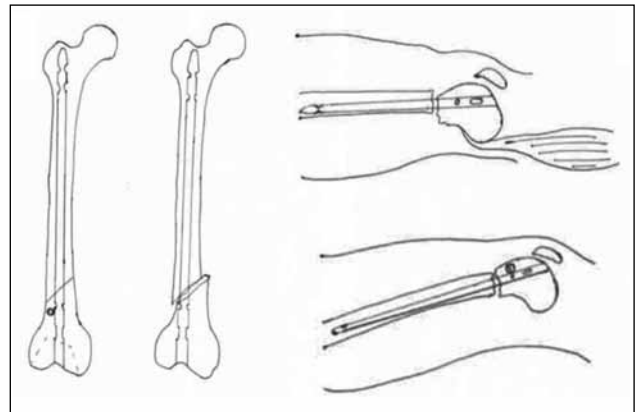


Figure 1 The blocking screw is usually placed on the concave side of the deformity in contact with the intramedullary nail.

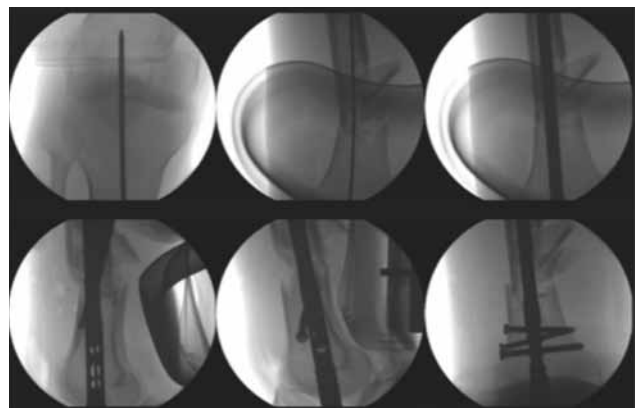


Figure 2 The entry portal of a blocking screw is lateralised for valgus and flexion deformities. The coronal deformity is corrected with insertion of the intramedullary nail, whereas the flexion deformity is corrected with a blocking screw.

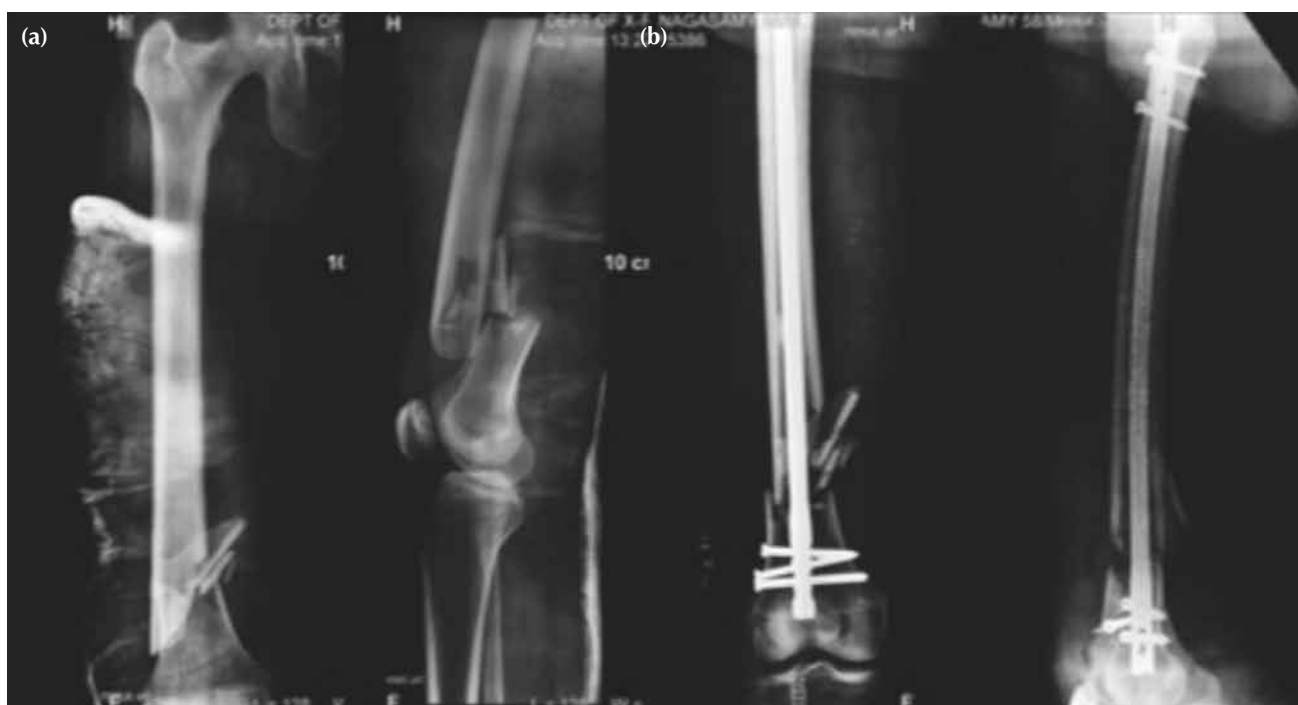

Figure 3 (a) A flexion deformity of the distal fragment and (b) restoration of axial alignment after retrograde nailing in conjunction with a lateral-to-medial blocking screw anterior to the nail.

have to be repositioned. The nail was then inserted and the deformity was usually corrected, provided the blocking screw was placed correctly (Fig. 2). The nail was then locked on both sides. In case of a coronal plane deformity, placing the blocking screws on the concave side of the deformity helps correct residual deformity after nail insertion.

RESULTS

All fractures united after a mean of 14 (range, 11–16) weeks without malalignment, defined as coronal or sagittal plane deformities of $>10^\circ$.⁷ 13 blocking screws were used; 10 patients were corrected for sagittal deformities and one for a coronal deformity. There was no screw breakage, screw bending, or wound infection. Insertion of blocking screws involved a mean additional time of 17 (range, 11–28) minutes. The position of the blocking screw needed to be changed intra-operatively in 3 patients owing to improper placement.

DISCUSSION

Although fixation with locking plates using

minimally invasive techniques for distal femoral shaft fractures has been successful, retrograde nailing remains a viable alternative, especially in obese patients and those with open fractures precluding the use of plating. The main disadvantage of nailing is the lack of construct stability. Moreover, persistent deformity leads to delayed/nonunion or malunion,⁸ as the metaphysis of the distal femur is roomy, and macro-motion at the fracture site may lead to non-union. Blocking screws decrease the canal diameter and act as an artificial cortex. They are often used for metaphyseal fractures of the tibia,⁹ especially for proximal tibial fractures with a tip-apex deformity, which may cause pressure necrosis of the skin and delayed union. Blocking screws have been used with antegrade nailing of the femur to improve axial alignment,¹⁰ and with retrograde nailing without major complications.¹¹ Blocking screws increase the construct stability and thereby enable early mobilisation and bone union. The addition of blocking screws can decrease deformation by 25% in proximal fractures and by 57% in distal fractures of the tibia, compared with constructs without blocking screws.¹²

In our study, mediolateral screws were used in 10 patients and an anteroposterior screw in one. Most of the coronal deformities were tackled by

altering the entry point of the blocking screw on the anteroposterior view. There is no definitive safe zone for placement of an anteroposterior blocking screw in the distal femur.¹³ Such a screw should be inserted bicortically in order to resist deformation during reaming and nail insertion, and placement in the most distal fractures should be avoided. After placement of the blocking screw, it is necessary to ream the desired nail passage again to provide adequate contact between the nail and the screw and to alter the path of the nail, which is already set by the initial reaming process. Mixed metals should not be used; blocking screws from the same interlocking set is preferred to minimise galvanic corrosion at the screw-nail interface.¹⁴

Blocking screws are a useful adjuvant of retrograde nailing in preventing residual malalignment of distal femur shaft fractures. The large space at the distal femoral shaft makes the nail to toggle and becomes unstable. Blocking screws increase the stability of the construct thereby minimising macro-motion at the fracture site. Anteroposterior screws should be inserted carefully. Screws of the same metallurgy should be used to prevent galvanic corrosion.

DISCLOSURE

No conflicts of interest were declared by the authors.

REFERENCES

1. Moed BR, Watson JT. Retrograde nailing of the femoral shaft. *J Am Acad Orthop Surg* 1999;7:209–16.
2. Ostrum RF, Agarwal A, Lakotos R, Poka A. Prospective comparison of retrograde and antegrade femoral intramedullary nailing. *J Orthop Trauma* 2000;14:496–501.
3. Ricci WM, Bellabarba C, Evanoff B, Herscovici D, DiPasquale T, Sanders R. Retrograde versus antegrade nailing of femoral shaft fractures. *J Orthop Trauma* 2001;15:161–9.
4. Wening P, Tschabitscher M, Traxler H, Pfafel V, Hertz H. Intramedullary nailing of proximal tibia fractures—an anatomical study comparing three lateral starting points for nail insertion. *Injury* 2010;41:220–5.
5. Krettek C, Miclau T, Schandelmaier P, Stephan C, Mohlmann U, Tscherne H. The mechanical effect of blocking screws (“Poller screws”) in stabilizing tibia fractures with short proximal or distal fragments after insertion of small-diameter intramedullary nails. *J Orthop Trauma* 1999;13:550–3.
6. Krupp RJ, Malkani AL, Goodin RA, Voor MJ. Optimal entry point for retrograde femoral nailing. *J Orthop Trauma* 2003;17:100–5.
7. Braten M, Terjesen T, Rossvoll I. Torsional deformity after intramedullary nailing of femoral shaft fractures. Measurement of anteversion angles in 110 patients. *J Bone Joint Surg Br* 1993;75:799–803.
8. Ricci WM, Bellabarba C, Lewis R, Evanoff B, Herscovici D, Dipasquale T, et al. Angular malalignment after intramedullary nailing of femoral shaft fractures. *J Orthop Trauma* 2001;15:90–5.
9. Krettek C, Stephan C, Schandelmaier P, Richter M, Pape HC, Miclau T. The use of Poller screws as blocking screws in stabilising tibial fractures treated with small diameter intramedullary nails. *J Bone Joint Surg Br* 1999;81:963–8.
10. Krettek C, Rudolf J, Schandelmaier P, Guy P, Konemann B, Tscherne H. Unreamed intramedullary nailing of femoral shaft fractures: operative technique and early clinical experience with the standard locking option. *Injury* 1996;27:233–54.
11. Ostrum RF, Maurer JP. Distal third femur fractures treated with retrograde femoral nailing and blocking screws. *J Orthop Trauma* 2009;23:681–4.
12. Stedtfeld HW, Mittlmeier T, Landgraf P, Ewert A. The logic and clinical applications of blocking screws. *J Bone Joint Surg Am* 2004;86(Suppl 2):17–25.
13. Marchant DC, Rimmington DP, Nusem I, Crawford RW. Safe femoral pin placement in knee navigation surgery: a cadaver study. *Comput Aided Surg* 2004;9:257–60.
14. Harris B. Corrosion of stainless steel surgical implants. *J Med Eng Technol* 1979;3:117–22.